

## Case Report of Infectious Myositis in the Austere Setting

Simon A. Sarkisian, DO<sup>1\*</sup>; Zachary J. Sletten, MD<sup>2</sup>;  
Preston Roberts, MD<sup>3</sup>; Tyler Powell, MD<sup>4</sup>

### ABSTRACT

Although skin and soft tissue infections are common in the deployed setting, infectious myositis is relatively uncommon. Bacterial infection of the muscle is the most common infectious etiology and can result in a spectrum of disease, to include abscess formation to necrotizing myositis, toxic shock syndrome, and death. Diagnosis can be elusive, particularly in the early stages. Recognition and proper management are crucial to prevent complications. The authors present a case report of infectious myositis diagnosed and managed in an austere deployed environment, as well as a discussion regarding current recommendations on diagnosis and treatment.

KEYWORDS: *infectious myositis; myositis; austere; antibiotics*

### Introduction

Myositis, or inflammation of the muscle, has a myriad of etiologies but is classically associated with autoimmune disorders or noninfectious causes. Infectious myositis is uncommon due to general muscle resistance to infection. However, when it does occur, it can result from a variety of pathogens to include viral, fungal, parasitic, and bacterial. Bacterial infections are the most common etiologies of infectious myositis and can result from hematogenous spread, contiguous spread, trauma, and vascular insufficiency. These bacterial infections include bacterial myositis, pyomyositis, and necrotizing myositis, which are further characterized by the infectious organism and clinical manifestations.<sup>1</sup>

### Pyomyositis

Pyomyositis is by definition a result of hematogenous spread, most often from *Staphylococcus aureus* or, less commonly, group A *Streptococcus* (GAS). However, it can result from a large variety of bacterial species.<sup>2-5</sup> Muscle is typically resistant to infection and a combination of bacteremia and muscular trauma has been proposed as a prerequisite etiology.<sup>1</sup> Muscular trauma degrades the muscle's natural ability to resist infection, giving rise to potential bacterial seeding during transient bacteremia. The bacteremia itself may result from a variety of sources, to include skin abrasions or intravenous (IV) drug use. Sources of muscular trauma include overuse injuries, blunt trauma, toxicity from medication, chemotherapy, or steroids.<sup>6</sup> The typical patient is a man in his 30s. Both diabetes and human immunodeficiency virus (HIV) appear to

be predisposing medical conditions.<sup>5</sup> Most cases will involve a single large muscle group of the lower extremity.

Pyomyositis proceeds in three stages beginning with an “invasive” stage, which occurs during the first 1 to 3 weeks and presents as local swelling, mild pain, and a woody texture overlying the involved muscle. Erythema can be lacking, and misdiagnosis is most likely to occur during this stage.<sup>6</sup> The patient may have variable fevers during this stage. During this early phase, imaging may not yet show a purulent collection or abscess.<sup>1</sup> Prior to the development of a purulent collection, management is with IV antibiotics alone, which should cover methicillin-resistant *Staphylococcus aureus* (MRSA). The “suppurative” stage (days 10 to 21) involves abscess formation with more pronounced fevers. Diagnosis is typically made at this stage.<sup>1</sup> Stage 3 is marked by progression to septicemia, shock, and potential death. Treatment at stages 2 and 3 involve surgical drainage.

Labs will often show leukocytosis with left shift, nonspecific elevation in erythrocyte sedimentation rate (ESR), but interestingly creatine kinase (CK) is typically normal.<sup>1</sup> Ultrasound, computed tomography (CT), and magnetic resonance imaging (MRI) can all be useful in showing a fluid collection. Although MRI may be the preferred imaging modality, CT is often more readily available. Pyomyositis is associated with a mortality rate of up to 4% and a low recurrence rate.

### Bacterial Myositis

Bacterial myositis, in contrast to pyomyositis, occurs without abscess formation, is less common, is more likely to involve more than one muscle group, and has a stronger predilection for adults.<sup>1</sup> The list of potential infectious causes is extensive and includes streptococcal species (most common), *S. aureus* (including MRSA), and *Clostridium* species (i.e., gas gangrene). Myositis secondary to GAS is a common etiology of bacterial myositis and can result in a spectrum of infection; GAS necrotizing myositis is the most lethal and aggressive.<sup>7-9</sup> The portal of entry is less clear and often there is no clear antecedent, although there may be a relationship to a preceding sore throat and nonsteroidal anti-inflammatory medication use.<sup>10,11</sup> A flulike illness, rash, and myalgias often precede local muscle pain, fever, and tense swelling, which can lead to compartment syndrome. In the case of necrotizing myositis, patients can deteriorate quickly to multiorgan failure and

\*Correspondence to Department of Emergency Medicine, 1 Cooper Plaza, Camden, NJ 08103 or simon.a.sarkisian2.mil@mail.mil

<sup>1</sup>CPT Simon A. Sarkisian is a staff physician in the Department of Emergency Medicine at Cooper University Hospital in Camden, NJ.

<sup>2</sup>CPT Zachary J. Sletten is a staff physician in the Department of Emergency Medicine at Brooke Army Medical Center in Fort Sam Houston, TX.

<sup>3</sup>MAJ Preston Roberts is a staff physician in the Department of Radiology at Madigan Army Medical Center at Joint Base Lewis-McChord, WA.

<sup>4</sup>MAJ Tyler Powell is staff physician in the Department of Internal Medicine at Brooke Army Medical Center at Fort Sam Houston, TX.

### Necrotizing Myositis

Necrotizing myositis, the most severe in the spectrum of bacterial myositis, has a markedly high mortality rate of up to 85%.<sup>7</sup> It is exceptionally rare, with only 21 documented cases from 1900 to 1985.<sup>12</sup> Necrotizing myositis presents in three stages, similar to those described for pyomyositis, but may lack overt cutaneous findings and can be easily misdiagnosed in the early stages. Alternatively, it may present with edema, violaceous skin, and bullae; however, this is more commonly seen in necrotizing fasciitis.<sup>6</sup>

Labs will often show elevation in inflammatory markers (e.g., ESR, C-reactive protein [CRP]), but tools such as the laboratory risk indicator for necrotizing fasciitis (LRINEC) appear quite insensitive.<sup>12</sup> Cross-sectional imaging with MRI or CT is useful in helping establish the diagnosis and monitor therapeutic response; CT is more readily available but MRI is the preferred modality. In the case of necrotizing myositis, imaging should not delay surgical consultation for emergent debridement.

### Case Presentation

#### Emergency Department Presentation

A 33-year-old woman presented to a Role 3 military treatment facility complaining of 2 weeks of left lateral thigh pain. The patient stated that 4 weeks prior to presentation she had a mechanical fall backward onto a tire, resulting in minor bruising and abrasions to her left lateral thigh and calf, which healed without treatment. However, 2 weeks later, she began to develop gradual onset of dull, left distolateral thigh discomfort with swelling. The patient denied any fevers, chills, night sweats, unusual weight loss, skin changes, back pain, pain with ambulation, recent illness, or history of IV drug use.

Her past medical history was remarkable for hematogenous MRSA osteomyelitis of her left distomedial femur 9 months prior, which was believed to be related to a preceding untreated infection of her finger. She was treated with a prolonged course of IV daptomycin and underwent incision and drainage and corticotomy of the affected area, from which she fully recovered.

On physical examination, her vital signs were significant only for tachycardia to 115 beats per minute as well as warmth, swelling, erythema, and tenderness to deep palpation of the left distal lateral thigh. A point of care ultrasound (POCUS) showed fascial enhancement between the biceps femoris and posterior vastus lateralis, concerning for myositis (Figure 1). An IV contrast-enhanced CT of the left leg was consistent with myositis and fasciitis of an infectious or inflammatory etiology (Figure 2). Figure 3 compares the contrasted CT findings with the POCUS findings. The patient's labs were significant for CRP of 154mg/L (normal range 0.0–7.5mg/L) and no leukocytosis. Two sets of blood cultures were negative. The LRINEC score was calculated to be 7.

### Differential Diagnosis

These findings, along with a recent history of MRSA osteomyelitis, led to a differential diagnosis that included: infectious myositis, inflammatory myositis, subperiosteal abscess, osteomyelitis, and atypical presentation of necrotizing fasciitis. After consultation with internal medicine and orthopedic surgery, the patient was started on IV linezolid 600mg twice daily and admitted to the medical unit for continued monitoring and management of presumed bacterial myositis versus stage 1 pyomyositis.

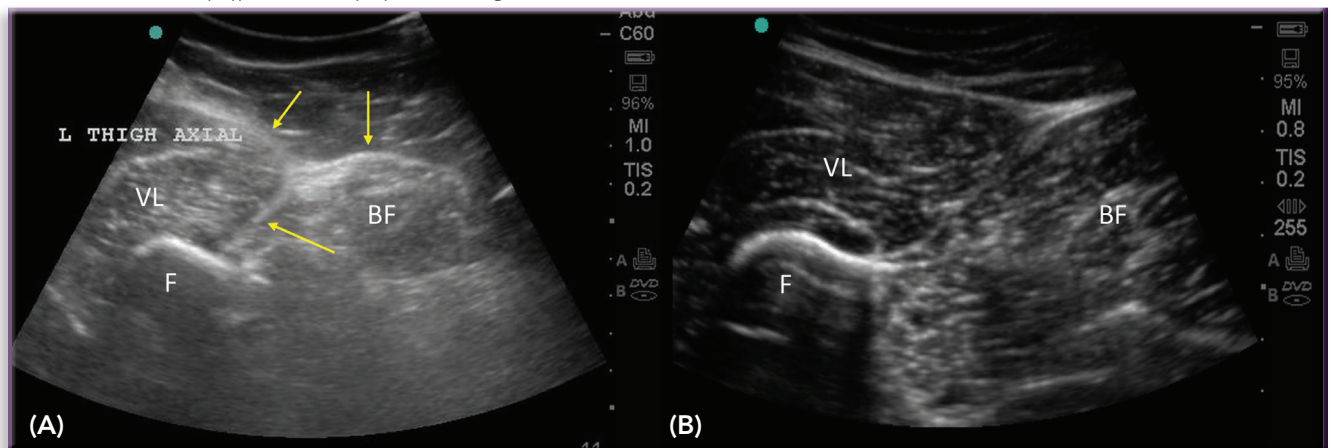
### Inpatient Course

Over the next 4 days of admission, the patient's pain, erythema, and swelling resolved and CRP decreased to 24.2mg/L. A repeat IV contrast-enhanced CT of the left leg on hospital day 3 revealed improvement in the infectious/inflammatory process of the vastus lateralis and biceps femoris with decreased fat stranding, decreased muscular enhancement, and partial resolution of the subperiosteal fluid collection. The patient was discharged back to duty on hospital day 4 with a 10-day course of oral linezolid.

### Outcome and Follow-Up

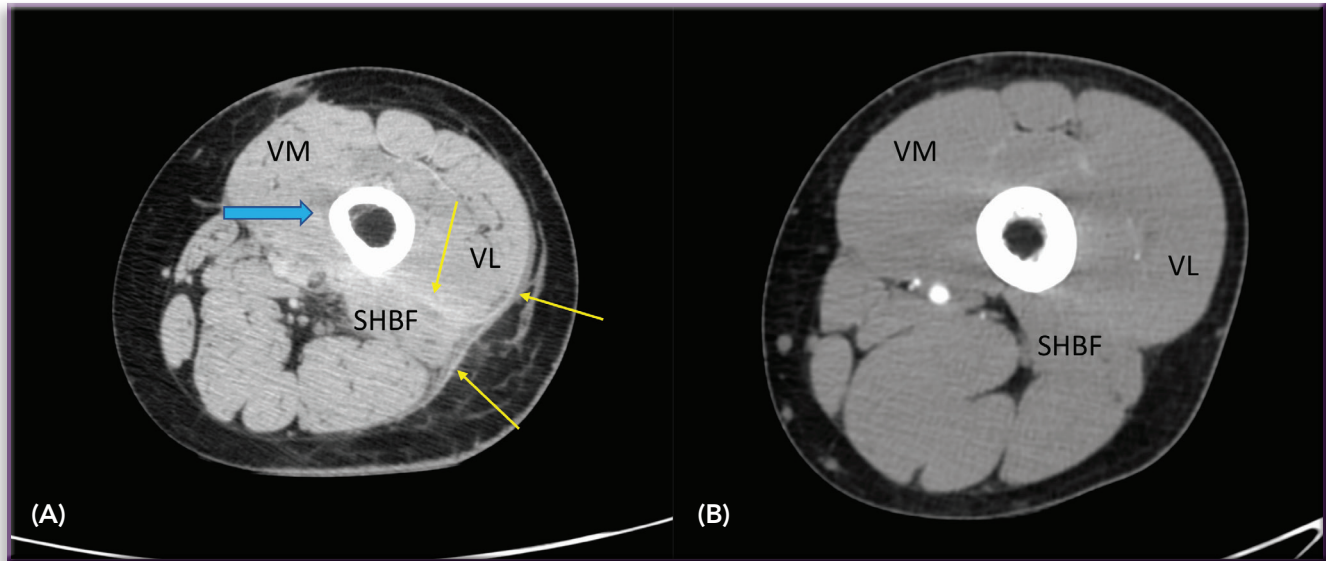
On follow-up in the orthopedics clinic 4 days after discharge, the patient remained symptom free and her CRP had decreased to 8.0mg/L. Following her total 14-day course of linezolid, the patient was prescribed an additional 2 weeks of oral trimethoprim-sulfamethoxazole. At her final follow-up appointment 1 month after discharge, the patient's CRP was

FIGURE 1 POCUS of affected area of left lateral thigh (A) versus normal control (B).



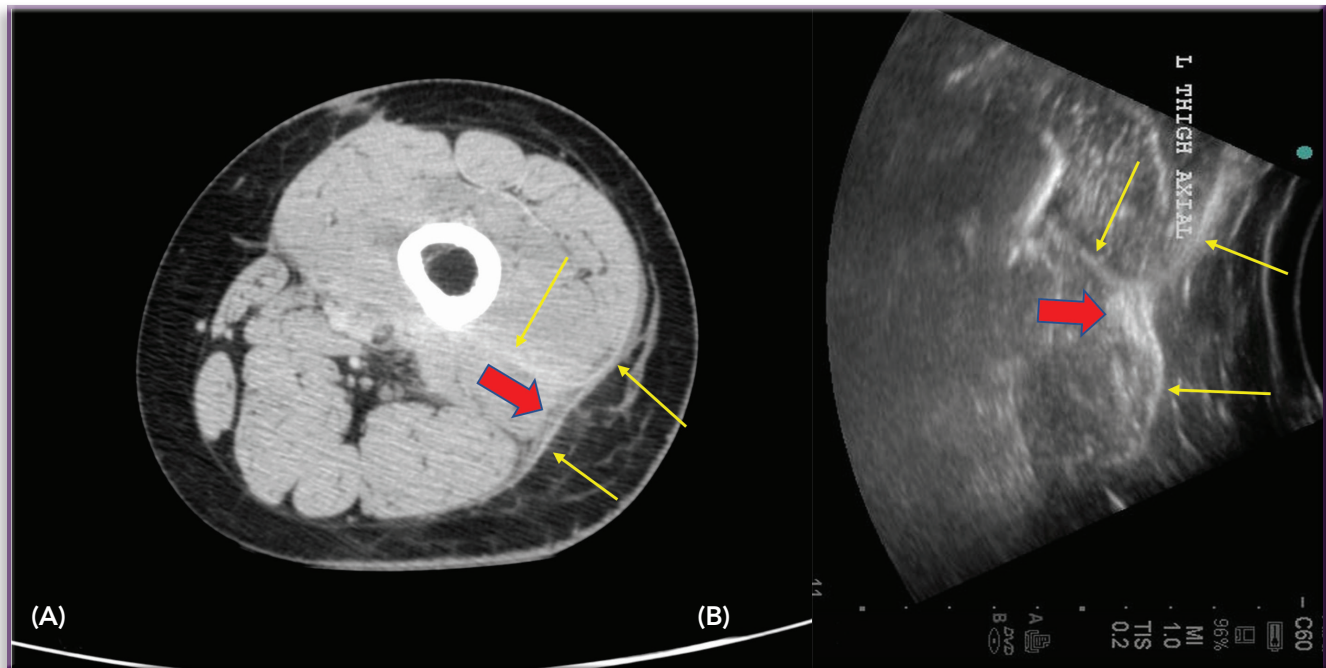
(A) There is fascial thickening which demonstrates increased echogenicity of both the deep fascia overlying the vastus lateralis (VL) and biceps femoris (BF) muscles and the intermuscular fascia extending between the posterior VL and anterior short head BF muscles (yellow arrows). There is increased echogenicity of the VL and BF muscles, suggesting edema and myositis without focal fluid collection. (B) Thin, smooth, deep, and intramuscular fascia without increased echogenicity of the muscles on the normal control. F, femur.

**FIGURE 2** Axial contrast-enhanced CT images of the distal thigh in the patient (A) and normal control (B).



(A) There is fascial thickening and enhancement of the deep fascia overlying the vastus lateralis (VL) and biceps femoris muscles as well as the intramuscular fascia between the posterior VL and anterior short head biceps femoris (SHBF) (yellow arrows). There are inflammatory changes of the fat, both superficial and deep to the fascia. Low attenuation marginating the medial femoral shaft with subtle increased enhancement of the vastus medialis (VM) muscle is noted (blue arrow). There is subtle increased enhancement of the posterior VL and anterior aspect of the SHBF consistent with myositis without drainable fluid collection. (B) The control demonstrates normal muscle and subcutaneous fat attenuation with thin, nearly imperceptible fascia.

**FIGURE 3** Comparison of contrast enhanced CT (CECT) (A) with POCUS (B).



(A) Fascial thickening and enhancement on the CECT correlates to thickened deep and intramuscular fascia, which is increased in echogenicity (yellow arrows). Prominent inflammatory fat stranding is noted both superficial and deep to the abnormal fascia (thick red arrows). Note that the POCUS image on the right has been rotated 90 degrees clockwise to match the orientation of the CECT. (B) Scarring from prior incisional drainage related to history of osteomyelitis is noted on the CECT anteriorly.

undetectable, and her CT scan showed substantial, near-complete resolution of the prior inflammatory process of the muscle, deep fascia, and surrounding tissue of the left thigh.

### Discussion

Literature regarding the treatment of secondary bacterial myositis is scant with recommendations and mostly extrapolated from that of pyomyositis. Similar to other skin and soft tissue

infections (SSTIs), evaluation for abscess with subsequent surgical drainage and prescription of appropriate antibiotics are paramount to treatment of this condition.<sup>13</sup> Unfortunately, due to a lack of culturing abilities and limited antibiotic selection, this may be complicated in the deployed environment where SSTIs are exceedingly common.<sup>14</sup> Consequently, an understanding of the typical bacterial pathogens encountered in the deployed military setting is crucial to effective treatment. Studies of SSTIs conducted during recent US military



All articles published in the Journal of Special Operations Medicine are protected by United States copyright law and may not be reproduced, distributed, transmitted, displayed, or otherwise published without the prior written permission of Breakaway Media, LLC. Contact publisher@breakawaymedia.org

campaigns have addressed this, finding nearly 70% of isolates to be MRSA.<sup>15</sup> Interestingly, evaluation of these deployment MRSA isolates has shown them to be mostly consistent with community-acquired MRSA strains found in the United States (strain USA300), rather than endemic to the local deployed environment.<sup>16,17</sup> Therefore, susceptibility profiles of these isolates are likely similar to those encountered in stateside care.

### Pharmacologic Considerations

The therapeutic cornerstone for inpatient complex MRSA SSTIs is IV vancomycin. Unfortunately, deployed hospitals (and other more austere locations) often lack the ability to monitor serum vancomycin levels, making identification of alternative treatment options necessary. Many of these alternatives, including daptomycin and ceftaroline, are also incongruent with the deployed environment, though linezolid has shown promise. Studies of linezolid in the treatment of SSTIs, especially those due to MRSA, have had favorable results with clinical and microbiological cure rates similar to or even better than vancomycin.<sup>18</sup> Furthermore, the 100% bioavailability of linezolid makes it a particularly useful option in austere environments, with studies of oral linezolid showing similar efficacy to intravenous vancomycin in complex SSTIs.<sup>19</sup> In the authors' experience, this medication is safe, especially for treatment durations of less than 14 days, and may provide an option for treatment of SSTIs in deployed locations. Thrombocytopenia, the most common side effect with prolonged use, appears unlikely with shorter treatment durations.<sup>20</sup>

In the case of bacterial causes of myositis, it is recommended that IV antibiotic therapy be used for the initial 2-week period, followed by an additional 2 weeks of oral therapy (totaling 4 weeks). Given environmental limitations, we elected to prescribe 4 days of intravenous followed by 10 days of oral linezolid for initial therapy. This was followed by 2 weeks of oral trimethoprim-sulfamethoxazole. The favorable response seen in our patient, as well as the 100% bioavailability of linezolid in both the oral and IV formulations, may suggest that oral linezolid is a reasonable initial therapy in complex MRSA SSTIs encountered during deployment. This strategy could be especially helpful in preventing evacuation of the critical warfighter.

### Imaging Considerations

The diagnosis of soft tissue infections is primarily clinical. Imaging studies provide a useful adjunct for determining extent of inflammation and help guide drainage if there are associated fluid collections.

Radiography, while often the initial imaging study obtained in the setting of suspected soft tissue infection, demonstrates limited specificity in cases of myositis or fasciitis. This is because soft tissue edema and obscuration of deep fat planes can be seen in traumatic or noninfectious inflammatory processes. The presence of soft tissue gas in the absence of penetrating trauma should raise suspicion for a more aggressive soft tissue infection.<sup>21</sup>

Ultrasonography offers diagnostic use as well, particularly in the evaluation for drainable fluid collections. POCUS is becoming a more common adjunct to the physical exam. Ultrasound findings seen in the setting of myositis and fasciitis include subcutaneous edema, inflammatory changes of the subcutaneous and deep fascial fat, fluid collections, muscle

enlargement and edema, fascial thickening and perifascial fluid, and subcutaneous emphysema.<sup>22</sup>

When available, CT and MRI play key roles in the evaluation of deep soft tissue infections such as pyomyositis and necrotizing or non-necrotizing fasciitis, with imaging findings often overlapping as in this case. Intramuscular abscesses, hallmarks of stage 2 pyomyositis, are well depicted with both CT and MRI, with other common findings including muscle enlargement and edema. Perifascial fluid and thickening, as well as fascial necrosis, are best depicted with MRI. The absence of perifascial fluid on MRI has a high negative predictive value if there is clinically suspected necrotizing fasciitis. Sensitivity for subcutaneous emphysema is greatest with CT. The most common CT findings of fasciitis include focal subcutaneous inflammatory changes and asymmetric fascial thickening with or without soft-tissue gas.<sup>13</sup>

### Lessons Learned

This particular case presented lessons learned that can be applied to similar cases of infectious diseases in the austere setting such as cellulitis, superficial abscess, and pyomyositis. For instance, although trending the CRP was helpful in evaluating for effectiveness of treatment, it is not completely necessary. Serial ultrasounds along with the physical exam can be useful to follow antibiotic effectiveness in a setting without laboratory, CT imaging, or surgical capabilities. Having a multidisciplinary team with a surgeon allowed this patient to avoid evacuation. Future considerations for similar patients in settings without surgical capabilities should incorporate telemedicine consultation to determine if and when evacuation is necessary.

### Conclusion

Diagnosis and management of infectious myositis can be challenging, particularly in the austere environment. As in the case discussed, a thorough history and physical are paramount as the diagnosis is clinical. Imaging modalities such as CT and MRI are useful adjuncts with an emerging role for ultrasound, which may offer value in the austere environment. Bacterial infections of the muscle, during early stages, can be safely managed with antibiotics alone. Linezolid, instead of antibiotics requiring laboratory monitoring, are preferred in the austere environment. A multispecialty collaborative approach involving radiology, internal medicine, and orthopedic surgery should be used to aid in the early diagnosis and management.

### Conflicts of Interest

The primary and corresponding author, CPT Simon Sarkisian, is also a staff editor for the *Journal of Special Operations Medicine*.

### Financial Disclosures

The authors have indicated they have no financial relationships relevant to this article to disclose.

### Disclaimer

The views expressed are solely those of the authors and do not reflect the official policy or position of Cooper University Hospital, Brooke Army Medical Center, Madigan Army Medical Center, the US Army, US Navy, US Air Force, the Department of Defense, or the US Government.

#### Author Contributions

SS initially managed the patient and helped write the manuscript. PR helped diagnose the patient's condition and write the manuscript. TP managed the patient after she was admitted and helped write the manuscript. ZS helped write the manuscript. All authors reviewed and edited the manuscript prior to submission.

#### References

1. Crum-Cianflone NF. Bacterial, fungal, parasitic, and viral myositis. *Clin Microbiol Rev.* 2008;21:473–494.
2. Ansaloni L. Tropical pyomyositis. *World J Surg.* 1996;20:613–617.
3. Chiedozi LC. Pyomyositis. Review of 205 cases in 112 patients. *Am J Surg.* 1979;137:255–259.
4. Christin L, Sarosi GA. Pyomyositis in North America: case reports and review. *Clin Infect Dis.* 1992;15:668–677.
5. Crum NF. Bacterial pyomyositis in the United States. *Am J Med.* 2004;117:420–428.
6. Crum-Cianflone NF. Infection and musculoskeletal conditions: infectious myositis. *Best Pract Res Clin Rheumatol.* 2006;20:1083–1097.
7. Adams EM, Gudmundsson S, Yocum DE, et al. Streptococcal myositis. *Arch Intern Med.* 1985;145:1020–1023.
8. Schattner A, Hay E, Lifschitz-Mercer B, et al. Fulminant streptococcal myositis. *Ann Emerg Med.* 1989;18:320–322.
9. Subramanian KN, Lam KS. Malignant necrotising streptococcal myositis: a rare and fatal condition. *J Bone Joint Surg Br.* 2003;85:277–278.
10. Hird B, Byrne K. Gangrenous streptococcal myositis: case report. *J Trauma.* 1994;36:589–591.
11. Jahnson L, Berggren L, Björnsell-Ostling E, et al. Streptococcal myositis. *Scand J Infect Dis.* 1992;24:661–665.
12. Khanna A, Gurusinghe D, Taylor D. Necrotizing myositis: highlighting the hidden depths – case series and review of the literature. *ANZ J Surg.* 2020;90:130–134.
13. Habeych ME, Trinh T, Crum-Cianflone NF. Purulent infectious myositis (formerly tropical pyomyositis). *J Neurol Sci.* 2020;413:116767.
14. May L, Porter C, Tribble D, et al. Self-reported incidence of skin and soft tissue infections among deployed US military. *Travel Med Infect Dis.* 2011;9:213–220.
15. Roberts SS, Kazragis RJ. Methicillin-resistant *Staphylococcus aureus* infections in U.S. service members deployed to Iraq. *Mil Med.* 2009;174:408–411.
16. Huang XZ, Cash DM, Chahine MA, et al. Methicillin-resistant *Staphylococcus aureus* infection in combat support hospitals in three regions of Iraq. *Epidemiol Infect.* 2011;139:994–997.
17. Murray CK, Griffith ME, Mende K, et al. Methicillin-resistant *Staphylococcus aureus* in wound cultures recovered from a combat support hospital in Iraq. *J Trauma.* 2010;69 Suppl 1: S102–S108.
18. Yue J, Dong BR, Yang M, et al. Linezolid versus vancomycin for skin and soft tissue infections. *Cochrane Database Syst Rev.* 2016:Cd008056.
19. Sharpe JN, Shively EH, Polk Jr HC. Clinical and economic outcomes of oral linezolid versus intravenous vancomycin in the treatment of MRSA-complicated, lower-extremity skin and soft-tissue infections caused by methicillin-resistant *Staphylococcus aureus*. *Am J Surg.* 2005;189:425–428.
20. Giunio-Zorkin N, Brown G. Real-life frequency of new-onset thrombocytopenia during linezolid treatment. *Can J Hosp Pharm.* 2019;72:133–138.
21. Hayeri MR, Ziai P, Shehata ML, et al. Soft-tissue infections and their imaging mimics: from cellulitis to necrotizing fasciitis. *Radiographics.* 2016;36:1888–1910.
22. O'Rourke K, Kibbee N, Stubbs A. Ultrasound for the evaluation of skin and soft tissue infections. *Mo Med.* 2015;112:202–205.





Summer 2021  
Volume 21, Edition 2

# J<sup>S</sup>OM

**JOURNAL of SPECIAL OPERATIONS MEDICINE™**



THE JOURNAL FOR OPERATIONAL MEDICINE AND TACTICAL CASUALTY CARE



*Inside this Issue:*

- › FEATURE ARTICLES: Tourniquet Practice Models
- › Atherosclerosis in Elite Special Operations Forces
- › 23.4% Hypertonic Saline for TBI
- › The Effect of Airdrop on Fresh Whole Blood
- › Military POCUS › Unconventionally Acquired Brain Injury
- › Prehospital Trauma Registry After-Action Reviews in Afghanistan
- › Telemedicine Capabilities of Special Operations
- › Targeted Intervention in Patients With mTBI
- › Back Pain in Italian Helicopter Aircrews › TXA Use in TEMS Providers
- › CASE REPORTS: TXA Use in TEMS Providers › Infectious Myositis › Bacteria on Female Urinary Diversion Devices
- › IN BRIEF: Far-Forward Blood Donation
- › ONGOING SERIES: Human Performance Optimization, Infectious Disease, Injury Prevention, Law Enforcement & Tactical Medicine, Research: How To, Veterinary Medicine, TCCC Updates, and more!

*Dedicated to the  
Indomitable Spirit,  
Lessons Learned &  
Sacrifices of the  
SOF Medic*